

CASE REPORT

Clear Cell Sarcoma of Kidney- A Report of Two Cases**Himansu Roy^{1*}, Palash Mondal², Soma Dey³ and Shrivasthi Roy⁴**

¹Department of Surgery, Medical College, Kolkata, India, ²Department of Pathology, Medical College, Kolkata, India ³Department of Pediatric Medicine, CCWH & RI, Thakurpukur, Kolkata, India and ⁴Department of Pathology, CCWH & RI, Thakurpukur, Kolkata, India

Abstract: *Background:* Clear cell sarcoma of kidney is a distinct renal neoplasm of childhood with an incidence of about 4% amongst all pediatric tumors. Though it is the most notorious for bone metastasis, clear cell sarcoma can metastasize to regional lymph nodes, lungs, liver & brain. The tumor is very malignant with a higher relapse rate and wider distribution of metastases than Wilm's tumor. *Case History:* We report here two cases of clear cell sarcoma of kidney, both alive after 03 years of initial diagnosis and treatment.

Key Words: Clear cell sarcoma of kidney, Childhood renal tumors.

Introduction

Clear cell sarcoma of kidney, also called bone metastasizing renal tumor of childhood in the past is a distinct primary kidney tumour in children [1]. Clear cell sarcomas have several features totally different from Wilm's tumor including therapeutic & prognostic differences [2-3].

Clear cell sarcomas comprise approximately 6% of pediatric kidney tumors [4] and has a peak age incidence between 3 & 5 years with a male- female ratio of 2:1. The tumor is very malignant with a higher relapse rate and wider distribution of metastases than Wilm's tumor eg. Bone, lymph nodes, lung, liver, brain etc. [3-4].

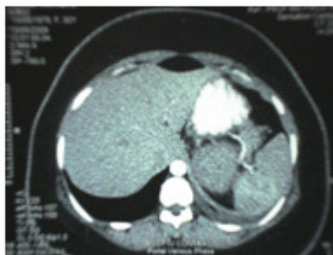Case History-I

Fig-1: CT scan of the patient with right renal mass

A 2 year old boy presented to the pediatric surgical OPD with a right abdominal swelling of 3 weeks duration in March 2007(Fig.1). There was no history of vomiting, weight loss or hematuria. On examination, patient had pallor and systolic blood pressure was 82 mm of Hg. Abdomen was distended with a firm non-tender swelling in the right hypochondrium and lumbar region. Blood & Urine tests and the chest radiograph were within normal limits. USG and later CT scan (Fig.1) showed a 11.8x9.0 cm heterogenous mass arising from the right

kidney. The tumor was removed en mass alongwith right ureter and 03 hilar nodes. Postoperative histopathological examination showed the tumor arising from the upper pole of right kidney with the capsule intact.

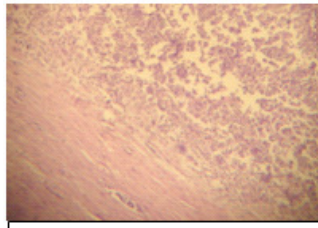


Fig-2: Clear cell sarcoma of kidney, H & E x 100.

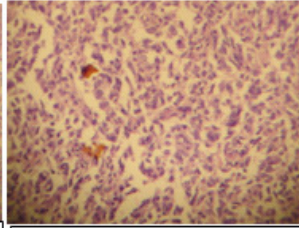


Fig-3: Clear cell sarcoma of kidney, H & E x 100.

The tumor showed features of a clear cell sarcoma of kidney-Classic type with focal myxoid and trabecular areas. No necrosis or infiltration of capsule or perinephric fat seen (Fig. 2 & 3). All the lymph nodes, ureter & hilar vessels were free.

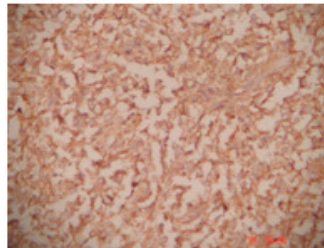


Fig-4: Immunohistochemically the tumor is focally reactive for Vimentin.

Immunohistochemistry showed focal positivity with vimentin, Cytokeratin, Desmin and S100 were negative (Fig. 4). The patient was given chemotherapy as per National Wilm's tumor study (NWTS-5) protocol consisting of Doxorubicin, Vincristine, Cyclophosphamide and Etoposide. Radiotherapy was also given after 10 weeks of chemotherapy. Presently (after 3 years) the child is doing well on follow up. Blood and urinary parameters are within normal limits. CT scan of brain and abdomen showed normal study. Whole body bone scan was also normal.

Case History-II

A 4 year old boy was referred to our hospital in April, 2008 with a diagnosis of Wilm's tumor following nephrectomy done 1 year back in 2007 in another hospital. On reviewing the case it was found that the patient had a 11.6cm x 8.5 cm mass in left kidney during diagnosis. The sections from this tumor submitted for review showed features of a clear cell sarcoma of kidney with classic and focal myxoid areas. The capsule, ureter, perinephric fat and two hilar nodes were free. No necrosis was present. Immunohistochemistry in our institution showed positivity for Vimentin while cytokeratin, S100, NSE, CD99 were negative.

Patient was given treatment as per NWTS-5 protocol followed by radiotherapy to the tumor bed. After three years of operation the patient is doing well with normal blood and urinary parameters. He has no signs of local recurrence. CT scans of brain and thorax are normal. Whole body scan is grossly normal with a small focus of increased tracer uptake in the head of left humerus. Both the patients have been advised regular follow up.

Review of Literature

Clear cell sarcoma of kidney (CCSK) is a well established pathological entity separate from the commonest pediatric tumor viz. the Wilm's tumor in the similar age group [2]. Apart from genetic & histological differences with Wilm's tumor, CCSK is resistant to conventional chemotherapy for Wilm's tumor and has a late onset of first relapse in stage I tumors [2-3]. Moreover they have a wider range of metastases compared to Wilm's tumor.

Usually they are unilateral & unicentric. Grossly these tumors are large with a grayish brown colour and sharply outlined. The cut surface is firm, homogenous with a myxoid appearance. Prominent cyst formation is noted in many of these tumors [5-6]. Most clear cell sarcomas of kidney have 'classic' pattern in which there is a monotonous array of cells with light staining or vacuolated cytoplasm and indistinct cell borders. There is an arborising fibrovascular stroma. The nuclei have fine chromatin with small nucleoli. Other histological types include spindle, epitheloid, sclerosing, myxoid, palisading & anaplastic [5-7]. Immunohistochemically these tumors are focally reactive for Vimentin (Fig 4). Markers like cytokeratin, CD 99, neuron specific enolase, desmin, S100 are negative [5, 8-10]. Ultrastructurally, the cells of the clear cell sarcoma have scanty organelles, sparse cytoplasmic filaments, primitive cell junctions and complex cytoplasmic processes [11]. Genetic studies on CCSK have not shown any consistent findings as in Wilm's tumor [12]. In the NWTS-5 protocol, CCSK at all stages is treated with radical nephrectomy followed by chemotherapy with vincristine, Doxorubicin and Etoposide for 24 weeks and radio-therapy. Overall survival is 69% [5]. Four important prognostic factors are treatment with Doxorubicin, stage, age at diagnosis and tumor necrosis.

Conclusion

Effective management of the clear cell sarcoma of kidney starts with correct histological diagnosis followed by treatment as per current NWTS protocol. Longterm follow up is mandatory because of late relapses even in stage I tumors.

References

1. Marsden HB, Lawler JB. Bone metastasizing renal tumour of childhood. *Br J Cancer* 1978; 38: 437-441.
2. Bechwith JB, Palmer NF. Histopathology and prognosis of Wilm's tumor: Results from the First national Wilm's Tumor Study. *Cancer* 1978; 41: 1937-1948.
3. Kusumakumary P, Chellam VG, Rojymon J et al. Late recurrence of clear cell sarcoma of kidney. *Med Pediatr Oncol* 1997, 28: 355-357.
4. Mierau GW, Weeks DA, Beckwith JB. Anaplastic Wilm's tumor & other clinically aggressive childhood renal neoplasms: Ultrastructural and immunocytochemical features. *Ultrastruct. Pathol* 1989; 13:225-248.
5. Argani B, Perlman EJ, Breslow NE et al, Clear cell sarcoma of kidney: A review of 351 cases from the National Wilm's Tumor Study group Pathology Center. *Am J Surg pathol* 2000; 24: 4-18
6. Sotelo- Avila C, Gonzalez- Crussi F, Sadowinski S, Gooch W M III, Pena P. Clear cell sarcoma of the kidney: a clinicopathologic study of 21 patients with long term follow up evaluation. *Hum Pathol* 1986; 16 1219-1230.
7. Sandstedt BE, Delemarre JFM, Harms D, Tournade MF. Sarcomatous Wilm's tumor with clear cells and hyalinization. A study of 38 tumors in children from the SIOP nephroblastoma file. *Histopathology* 1987; 11: 273-285
8. Looi LM, Cheah PI. An immunohistochemical study comparing clear cell sarcoma of the kidney and Wilm's tumor. *Pathology* 1993; 25: 106-109.
9. Takagi M, Takakuwa T, Ushigome S et al. Sarcomatous variants of Wilm's tumor. Immunohistochemical and ultrastructural comparison with classical Wilm's tumor. *Cancer* 1987; 59: 963-971.

10. Viswanathan S, Dave B K, Desai SB. Clear cell sarcoma of the kidney- a study of seven cases over a period of 3 years. *Indian J Pathol Microbiol* 2007; 50: 270-273.
11. Haas JE, Bonadio J F, Beckwith JB. Clear cell sarcoma of the kidney with emphasis ultrastructural studies. *Cancer* 1984; 54: 2978-2
12. Barnard M, Bayani J, Grant R, Zielenska M et al, Comparative genomic hybridization analysis clear cell sarcoma of the kidney. *Med Pediatr Oncol* 2000; 34: 113-116.

*All correspondences to: Dr. Himansu Roy, Department of Surgery, Medical College, Kolkata, India
E-mail: dr_hroy007@yahoo.co.in